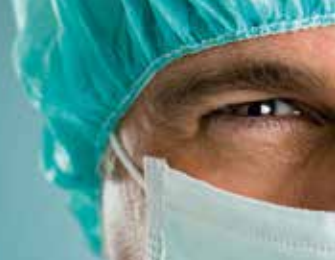



BEZNOSKA

We bring back joy to movement



Hip Hemiarthroplasty type CSB

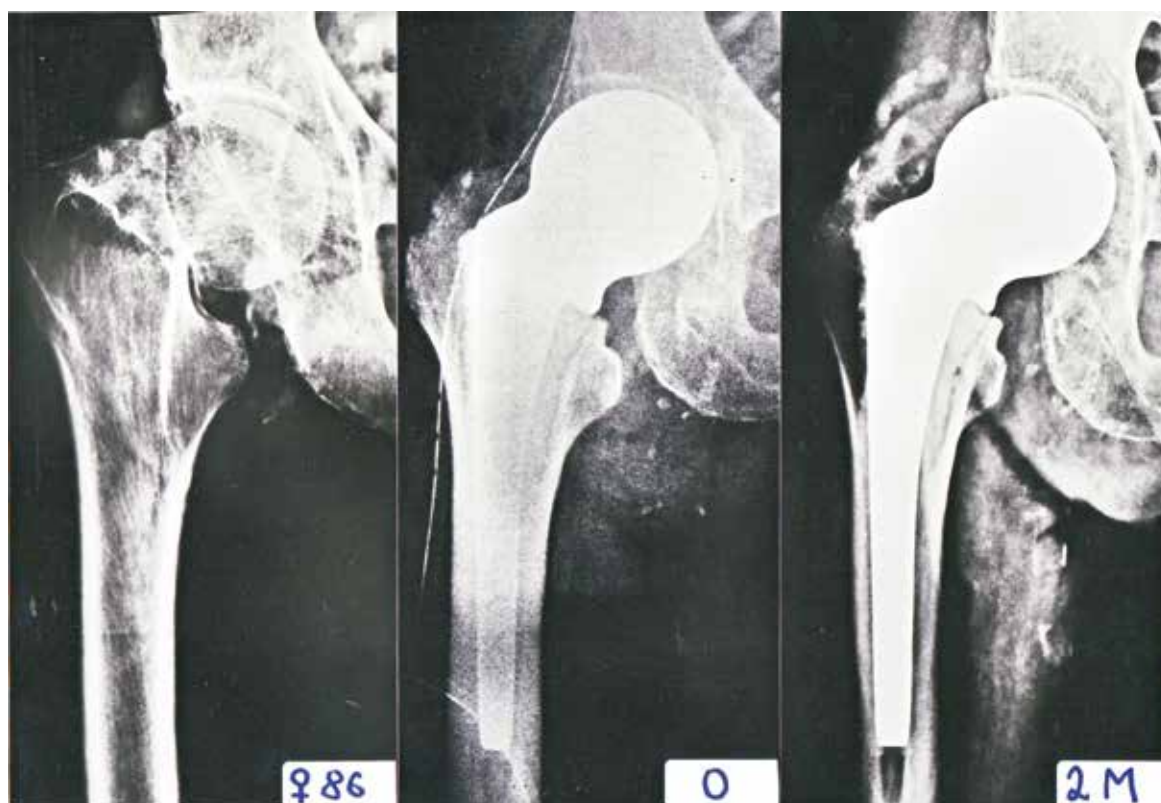


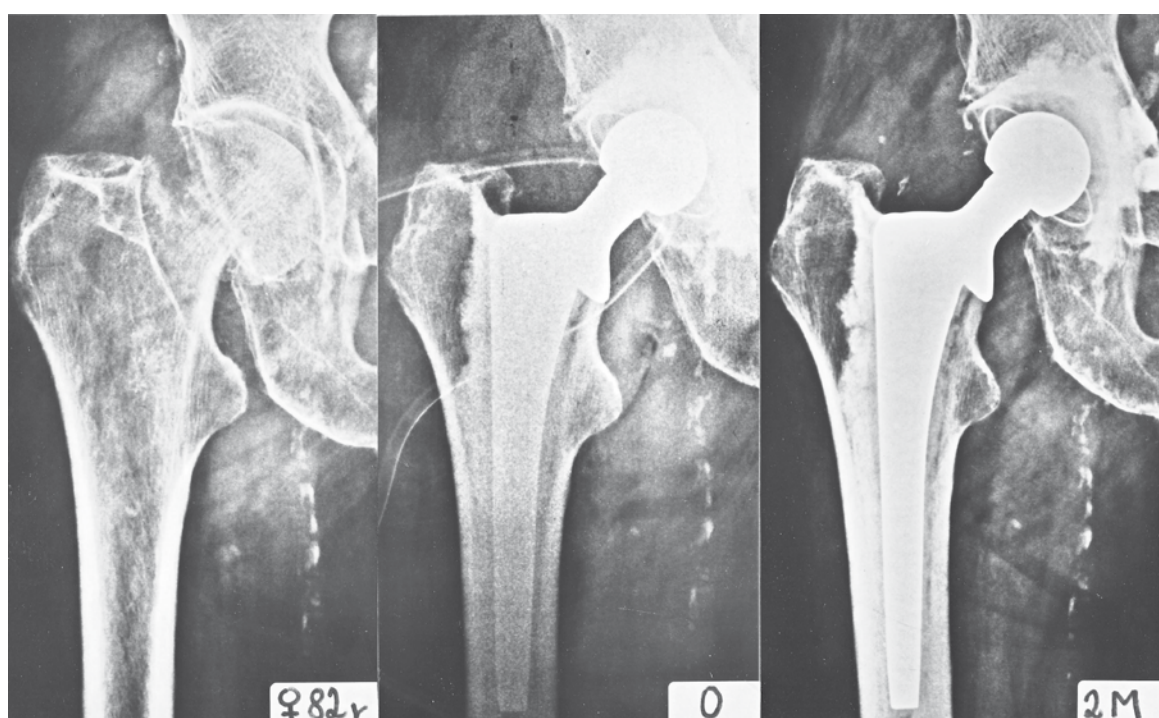
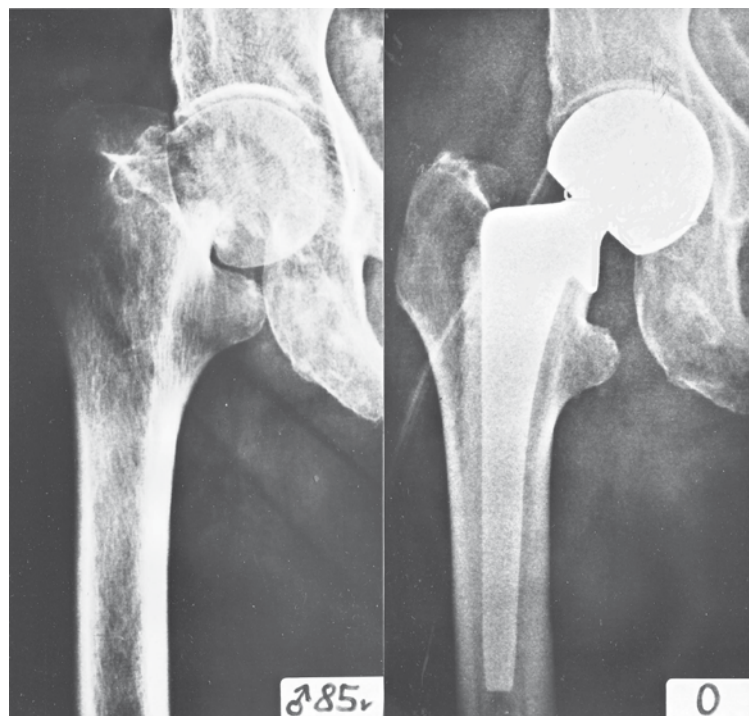
Preface

Hip hemiarthroplasties manufactured by the Beznoska Ltd. were developed more than 30 years ago. Since then they have been very effectively fulfilling their historical role and meeting the requirements of several generations of Czech and Slovak orthopaedists and traumatologists.

The need for comprehensive post-traumatic solutions to hip joint injuries and new clinical practice requirements emerged while evaluating the long-term results of traumatologic arthroplasty hitherto achieved, leading us to cooperation with the Orthopaedic Traumatological Clinic of the 3rd Medical Department (Faculty) of Charles University (LF UK) and the University Hospital of Královské Vinohrady (FNKV), Prague, and to essential innovation of our down-to-date production.

The outcome of this cooperation was the creation of a modular system devised primarily as treatment of intracapsular fractures of the femoral neck. The concept of the system is based on a universal stem of a monobloc hemiarthroplasty and a separate modular stem. The latter stem can be used for creating a modular hemiarthroplasty prosthesis, modular biarticular implant, or total implant. The form of the stem is based on a clinically tested implant, type CSC.





■ The Characteristics of the Implants

The design of the original monobloc hemiarthroplasty stemmed from the material and technological possibilities of the day. Although the design has served tens of thousands with good results, it did have certain shortcomings:

1. A small lateralization of the head mid-point from the stem longitudinal axis and a rather wide angle between the stem and the neck of the prosthesis shortened the lever of the abductors. This increased pressure on the acetabular cartilage, thus reducing tonization of soft tissue, thereby increasing the risk of post-surgery luxation.
2. The angle between the collar and the stem did not correspond to the "CCD" angle of the prosthesis. Unless this fact was taken into consideration during the resection of the neck, the position of the head mid-point of the prosthesis would be too high in relation to the apex of the large trochanter, thus causing the pressure on the acetabular cartilage to be too high, again.
3. Moreover, if the bone marrow canal was too narrow for the diameter of the stem, the hemiarthroplasty prosthesis could not be used at all.
4. In the event of resurgery of the monobloc hemiarthroplasty prosthesis requiring extraction of the stem from well-preserved cemented layer, the shape of the stem did not allow simple stem extraction and replacing it with a modular stem of identical shape and size. Instead, it was necessary to remove all the cement or use a thinner stem that had to be fitted into the original (old) cement layer.

The new design of the stem should retrieve all of the above shortcomings, as it:

- **simplifies the neck resection**
- **facilitates tonization of soft tissues without making the extremity longer**
- **extends the arm strengths of abducting muscles, thus diminishing pressure on the acetabular cartilage and extending the prosthesis service life**
- **allows for using the stem with narrow bone marrow canals, too**
- **makes resurgery easier**
- **optimizes the cement layer thickness if the centralizer is used**

The new monobloc hemiarthroplasty prosthesis was clinically used in 2007 at the Orthopedic Traumatologic Clinic 3rd LF UK and FNKV on a total of 20 patients. None of them has suffered any post-surgery luxation or other complication to date.



■ Indication

There is as yet no clear-cut approach in the world literature to indication of arthroplasty in cases involving dislocated intracapsular fractures of the femoral neck, even though apparently preference has been lately given, in patients over 70 of age, to arthroplasty over osteosynthesis. Similar discussions are being held as to whether to use total arthroplasty or hemiarthroplasty. However, in this respect, too, preference is evidently being given to total prostheses, as long as local and general conditions so allow. A universal approach to the advantages or disadvantages of biarticular prostheses has not been clearly defined yet.

It is generally believed that the risk of complications is lower with hemiarthroplasty than with total prostheses. Their drawback is premature wearing of the acetabular cartilage, followed by erosion of the subchondral bone, causing pain and limitation of functionality.

A total implant presents a greater strain to the patient, but its longer functionality is a benefit on the long run. In any case, there is an essential difference between rating the functional results in patients operated for coxarthrosis and those operated due to an injury.

Therefore, the choice of implant for traumatic arthroplasty of the hip joint depends on the surgeon's experience and preferences. The recommendations below are not binding; the Beznoska Ltd. or the authors of this manual do not assume any liability in this respect.

Monobloc hemiarthroplasty is designated primarily for biologically older patients who have minimal functionality expectations. Biologically older patients are mostly patients over 80 years

of age, with ASA IV and more, low pre-injury physical activity, and presumed short life expectancy.

Modular hemiarthroplasty, mono or biarticular one, is designated for younger patients, usually aged 60 to 70 years, with presumed longer life expectancy, and higher functionality expectations, who have – at the time of the injury a higher risk of complications, due to general or topical reasons, if a total prosthesis was used. Modular stems makes easier a prospective resurgery and/or transition to the total prosthesis.

Hemiarthroplasty contraindication is hip joint arthritis – moderate arthritic deformations are acceptable exceptionally and in very elderly patients only. Also, it is essential to assess the shape of the acetabulum first (dysplastic hips); moreover, one has to be extra cautious with patients having a rheumatic disease (RA, morbus spondylitis, known also as Bekhtyerev disease, etc.).

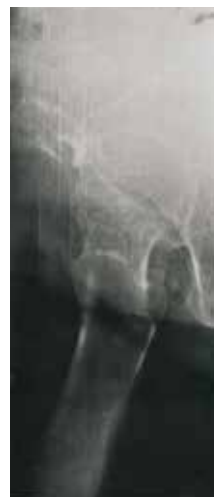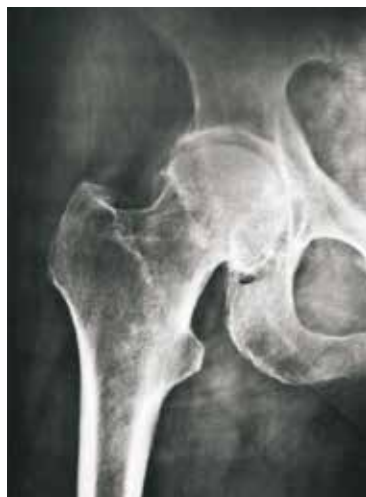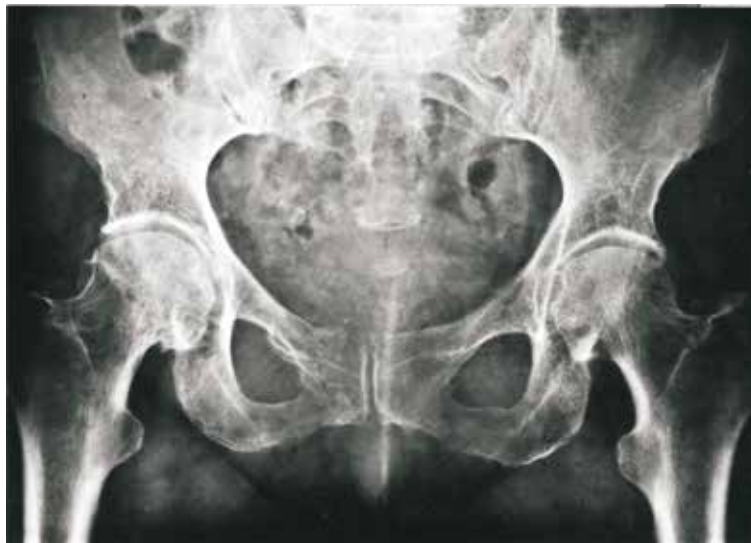Total prosthesis is designated, independently of age, for patients who are cooperative, physically active, and in good condition, generally and topically, and having a greater risk of avascular necrosis of the femoral head. In this context, world literature specifies age limit of 65-70 years. No clear-cut recommendation exists, as it always also depends on the type of fracture, the time elapsed since injury, patient's cooperation, etc.

■ Surgical technique for implanting a cemented monobloc hemiarthroplasty prosthesis

X-ray examination: Indication and planning of the surgery has to be substantiated by a correct x-ray examination. By patients having a fracture of the proximal femur, this involves:

- a comprehensible x-ray view of the patient's pelvis
- AP view of the joint showing the proximal part of the diaphysis within the range of the implant; whenever feasible, the view must be taken in basic position (when taking the x-ray, use antirotation boot for fixation the extremity in the desired position)

- an axial view of the hip joint may be necessary, if dislocation of the head is not clearly visible in the AP view
- in indicated cases, also a x-ray view of the lower backbone may be needed.





This series of x-ray views should enable you correctly to assess the type and degree of dislocation of the fracture, the condition of the opposite hip joint (degenerative symptoms, preceding surgery), the condition and shape of the bone marrow canal where the stem will be inserted (angulation, presence of implants preventing from the stem induction, etc.), any signs of degenerative deformations in the lower backbone (spinal anesthesia, post-surgery pain).

Implant indication and selection

Covered in preceding chapter.

Use of antibiotics

Prophylactic administration of ATB is matter of course in patients with a greater risk of infection; also, bone cement containing ATB can be used.

Surgical technique

Hemiarthroplasty prosthesis may be implanted using the Watson-Jones anterolateral approach or the Kocher-Langenbeck posterolateral one. The choice depends on the given medical institution practice. Positioning the patient and the surgical technique proper have been frequently described in national literature, hence we present relevant references.

The implantation procedure

Whether using the anterior or posterior approach, we follow standard course of procedure with maximum caution given to avoid any damage to soft tissues.

Opening of the canal

The canal must be treated with particular care, as the quality of the suture is – after closing the wound – an important factor in preventing from luxation. The canal is cut using a T-shape resection and the two ends of the

short cut are fixed with the aid of two suspension stitches.

Extraction and head measuring

Extirpate the head, preferably in one piece, using a spiral extractor, and measure it carefully in at least perpendicular positions. To get the accurate size of the head is utmost important. Were the head too small, the bottom of the acetabulum would begin to protrude prematurely; were it too large, it would not fit the socket properly, causing the joint to be unstable and, moreover, damage the acetabular edges. Our new gauges, developed in accordance with latest world literature, facilitate more accurate and easier measuring of the head diameter than the old ones. Statistically, the most common diameters are 48, 46, and 44 mm. The right choice of the head size can be verified through trial fitting. If the size is right, the head cannot be luxated without using force and luxating the head out of its position would be accompanied by a typical acoustic phenomenon (sound).

Revision of the acetabulum

After extracting the head, revision of the acetabulum follows. The stump of the capitis femoris ligament, if any, is usually left in its place, as it does not present any potential interpositum. On the contrary, its excision might lead to unnecessary bleeding of the relevant vein. Now we examine the condition of the articular cartilage and watch out for small bone ragments that could have fallen into the acetabulum while extracting the head.

Resection of the femoral neck

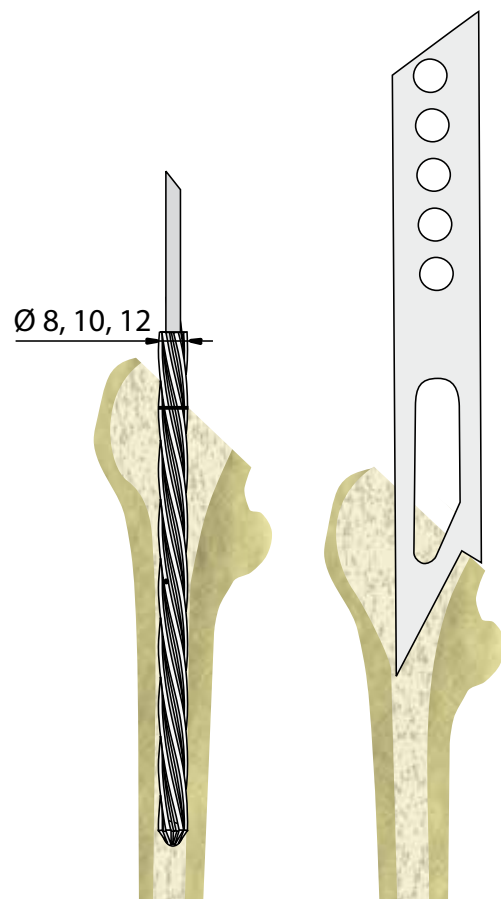
The level of resection is extremely important for ensuring long-term functionality of the joint. As a rule, the head mid-point of implant should be just below the top of large trochanter. A higher level of the head mid-point would increase pressure on the acetabulum – in fact, this error happens to be the most common cause of the acetabulum damage!!! Vice versa, “sinking-in” the head too far would cause insufficient tonization of soft tissues, leading to instability of the joint. In this context, it is essential to make good pre-surgery planning, assess the collision-proneness of the diaphysal angle of the healthy side and determine the position of the resection level to the small trochanter accordingly. If using the posterior approach, it is easier to uncover the small trochanter and to “read” the resection level.

With the new type of implant, the resection must be made so that the angle to the longitudinal axis of the femoral diaphysis is equal to the angle between the collar and stem. It is a good idea to mark the angle and the resection level of the osteotomy with the chisel first. The osteotomy line should be running mediolaterally from the transition point of the neck base and the large trochanter toward the above mentioned small trochanter angle. Getting used to assessing the angle and level of resection correctly may be somewhat difficult, so particular care must be taken initially.

Preparation of the bone marrow canal

After cutting off the neck stump, open the bone marrow canal carefully, preferably using a semi-circular chisel. If the spongiosis is very thin, a long spoon should suffice. If we want to facilitate preparation of the bone marrow canal with a rasp, use a special cutter with a cylindrical stem up to size 2 to match the size of the implanted stem. The depth

of the cut is marked with a line (ring) on the cutter. Once the cut is made, use a rasp – up to size 2, again. When using the rasp, we reckon with a future anteversion of 10-15°, turning the rasp accordingly. Adjust the position to the level of the shinbone at a flexion of 90° in the knee. After finishing work with the rasp, remove spongiosis fractions with a spoon. Rinse the bone marrow canal, insert the stem, and test the fit of the joint, both mobility and stability-wise. Then take the implant out.

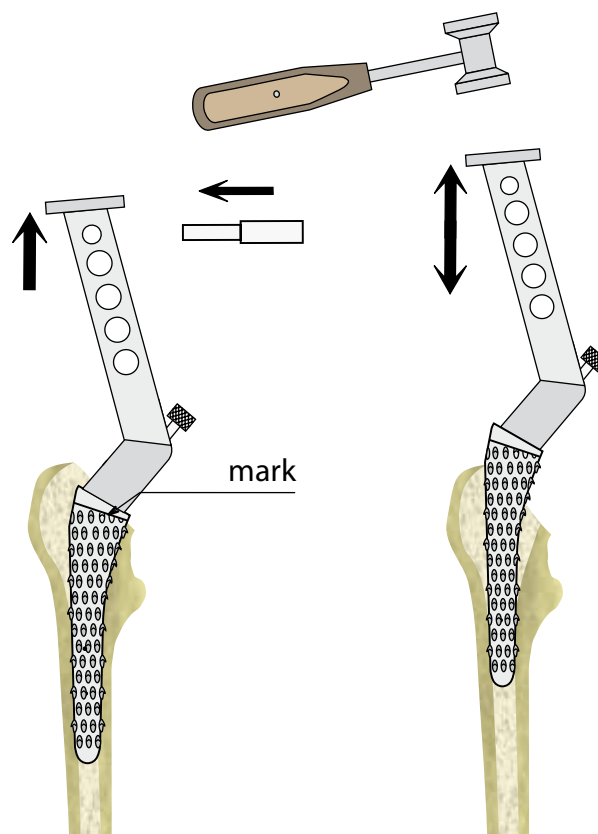




Final preparation of the bone marrow canal is done with the aid of a set of rasps. In order to prepare the bone marrow canal properly, it is necessary to use the difference sizes of rasps consecutively, so as to ensure the desired thickness and correct distribution of the bone cement. Once the stem is inserted, the cement filling will be 2 mm thick distally and 4 mm proximally. Work with the rasps is finished when the osteotomy line is even with the line on the rasp.

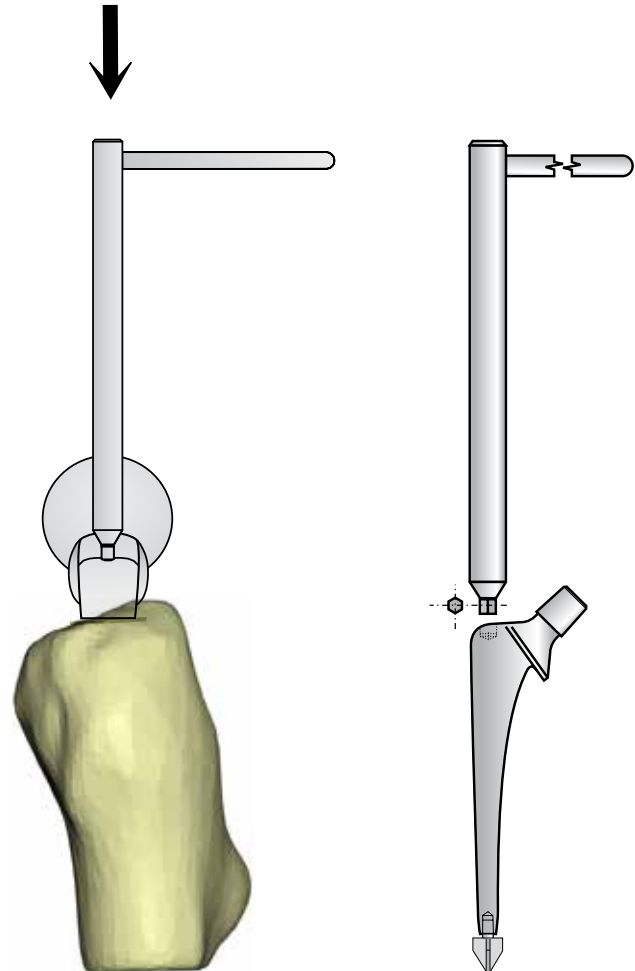
Cementing

Close the bone marrow canal with a plug – usually, the cut-off head is used for making the plug. The plug should be inserted up to about 1 cm below the tip of the stem or centralizer. If no plug was used, the cement would sink deep into the bone marrow canal of the diaphysis and this would make correct pressure adjustment impossible. Before applying cement into the bone marrow canal, it is advisable to insert a plastic drain into the canal up to the level of the plug. The drain is carrying excess blood away and facilitates application of the cement all the way up to the plug. The cement must have proper consistency (thickness). Applying cement that is so thin that it sticks to the surgeon's gloves is wrong. Thin cement indicates insufficient mixing of both ingredients, so that toxic monomer could penetrate into the patient's blood circulation, while inserting the stem, which might cause microembolization in the lungs. This cement tends to leak out around the stem, without getting properly interdigitated with the bone marrow canal spongiosis. Plastic-like consistency of the cement is optimal, i.e., reaching a so-called working phase of thickening. For the most commonly used cement, Palacos, this takes about 5 minutes, but this interval may vary considerably depending on temperature in the surgery room. It is common practice to pinch off a small piece of the cement and to rub it between one's fingers to see how its consistency changes.



Adjusting anteversion and inserting the stem

Before inserting the stem, we have to adjust anteversion correctly, i.e., to approx. 10-15°. Excessive anteversion would put too much pressure on the front part of the acetabulum, causing it to erode too soon. Retroversion, especially if using the posterior approach, causes post-surgery instability. With the anterior approach, checking whether anteversion is adjusted correctly can be done the same ways as when performing a total replacement surgery. With the posterior approach, we bring the knee to 90° flexion and adjust anteversion according to the level between the shinbone and the thigh. Positioning during insertion is done with the aid of the guiding wire. The end of this wire is hexagonal and is fitted into an opening of the same shape on the upper edge of the stem collar. Depending on adjustment, the cross bar may be positioned either on the same level as the neck, or perpendicularly to that level – anteversion can be thereupon adjusted according to the position defined by the flexed shin bone through slight rotation until the necessary anteversion is reached. With the anterior approach, checking whether anteversion is adjusted correctly can be done the same ways as when performing a total replacement surgery. Apply the centralizer to the tip of the stem, press it in gently, and then turn by 90°. Using gentle continual pressure, push the guiding wire – fitted into the upper edge of the collar – into the bone marrow canal. Do not forget to take the drain out of the canal in time. After fitting the collar over the Adams arch, carefully remove excess cement using a spoon, and check the acetabulum, too. Excess cement forgotten in the acetabulum is a fairly common cause of luxation.





Finishing the surgery

Once the cement hardens and trial fitting has been done, we check the joint for mobility and stability. Provided that everything is all right, we perform a meticulous suture of the canal – if posterior approach was applied, we reinsert the short external rotators, insert R-drains, and close the wound.

Post-surgery care

Post-surgery positioning is very important. If anterior approach was used, we apply an antirotation boot into the position of moderate inward rotation; if posterior approach was used, we put into the position of moderate outward rotation. The point is that the head should rest on the undisturbed part of the cemented canal.

Thereupon, we take an x-ray view.

Mobilize the patients as soon as possible, usually the second day after surgery, but there are considerable differences between individual patients. Most patients do not know how to take weight off the operated hip, so they are inclined to move only to the extent that their pain threshold permits.

Post-surgery patients should be followed up regularly, as that is the only way of gaining information about the results of one's work.

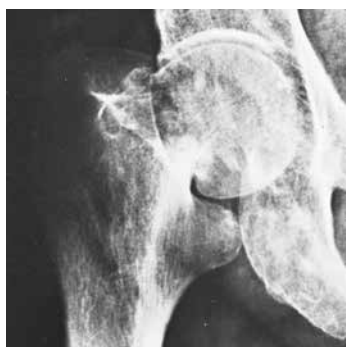Bibliography

1. **Bartoniček J, Bartoš M:** *Surgical Approaches to Hip Joint Arthroplasty (Anatomical Notes).* Acta Chir Orthop. Traumatol. Čech 53:405-415, 1986
2. **Bartoniček J, Skála-Rosenbaum J, Džupa V, Svatoš F, Bartoška R:** *Hemiarthroplasty of Intracapsular Fractures of Femoral Neck.* Rozhl Chir 84: 88-95, 2005
3. **Bartoniček J, Džupa V, Skála-Rosenbaum J, Douša P:** *Hemiarthroplasty for displaced intracapsular femoral neck fractures.* Osteo Trauma Care 13: 214-218, 2005
4. **Bhandari M, Devereaux PJ, Swiontkowski MF, Tornetta P, Obremskey W, Koval JK, Nork S, Sprague S, Schemitsch EH, Guyatt GH:** *Internal fixation compared with arthroplasty for displaced fractures of the femoral neck.* J Bone Joint Surg 85-A: 1673-1681, 2003
5. **Čech O, Pavlanský R:** *Hip Joint Arthroplasty.* Prague, Avicenum 1979
6. **Džupa V, Bartoniček J, Skála-Rosenbaum J, Příkazský V:** *Mortality of Patients with Fracture of Proximal Femur During First Year After Injury.* Acta Chir Orthop Traumatol Čech 69: 39-44, 2002
7. **Jeffery JA, Ong TJ:** *Femoral head measurement in hemiarthroplasty: assessment of interobserver error using 3 measuring système.* Injury 31: 135-138, 2000
8. **Parker MJ:** *The management of intracapsular fractures of the proximal femur.* J Bone Joint Surg 82-B: 937-941, 2000
9. **Sosna A, Čech O:** *Dorsal surgical approach by application of hemiarthroplasty prosthesis.* Acta Chir Orthop Traumatol Čech 40:537-543, 1973
10. **Tidemark J, Ponzner S, Svenson O, Söderquist A, Törnkvist H:** *Internal fixation compared with total hip replacement for displaced femoral neck fractures in the elderly.* J Bone Joint Surg 85-B: 380-388, 2003

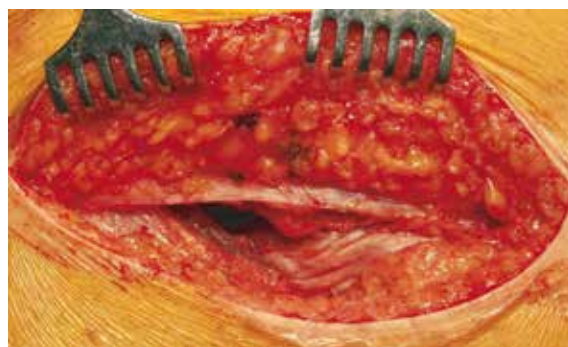■ Illustrations of the Surgical Technique

Prof. MUDr. Jan Bartoniček, DrSc.

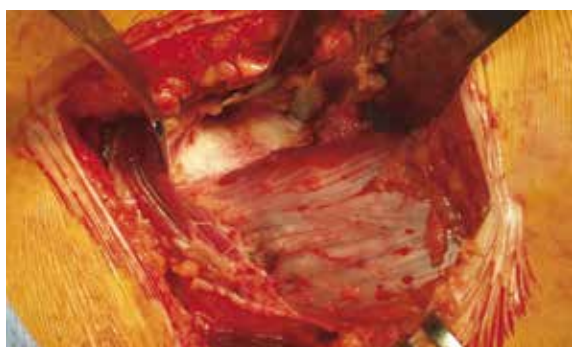Orthopedic Traumatological Clinic, 3rd LF UK and FNKV, Prague - Vinohrady



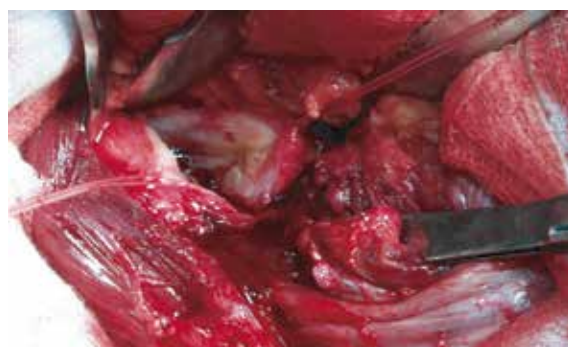Pre-surgery x-ray of dislocated intracapsular femoral neck fracture.



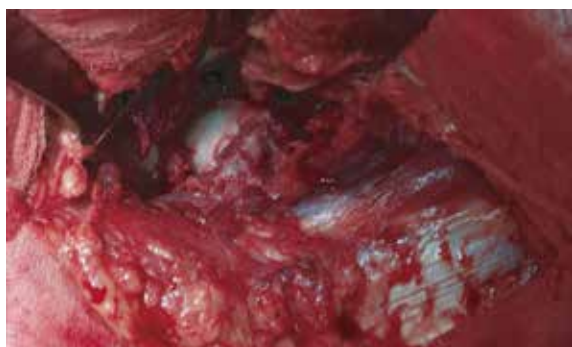Anterolateral Watson-Jones approach.



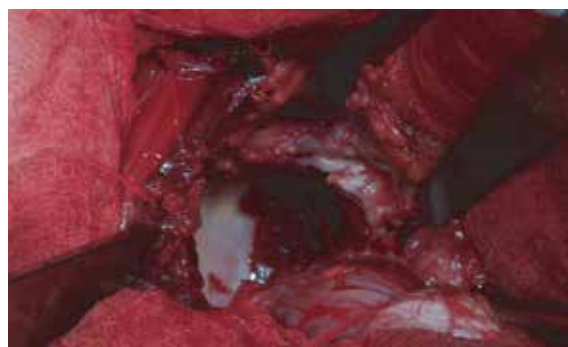Anterior view of the hip joint capsule.



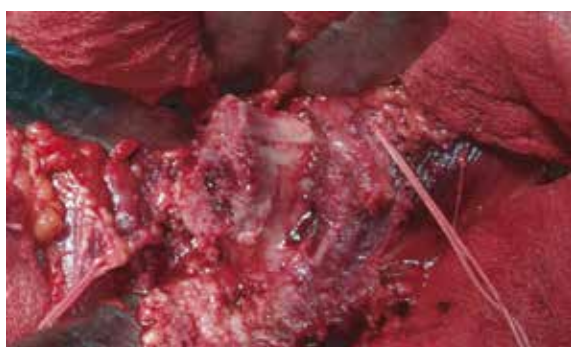Arthrotomy with part of capsule on suspension stitches.



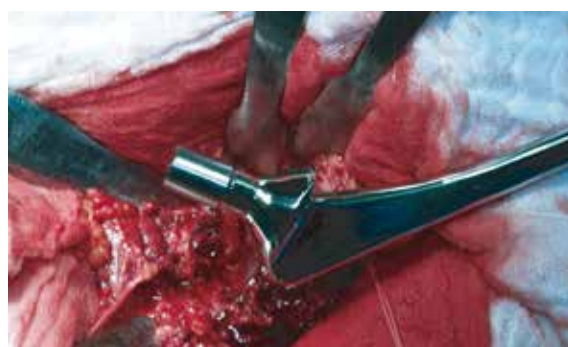Dislocated intracapsular femoral neck fracture.



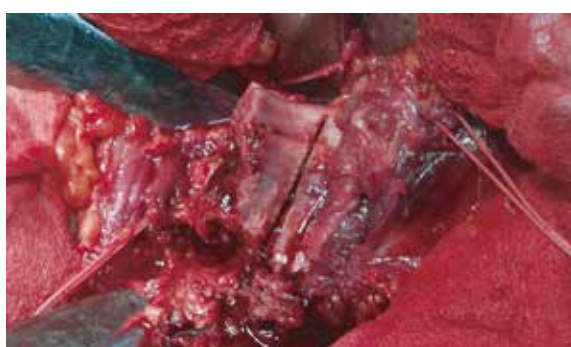Revision of the acetabulum after head extraction.



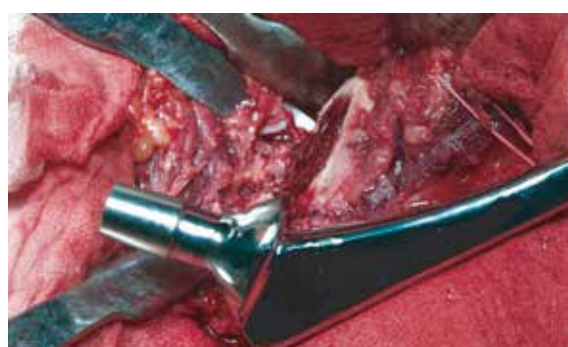Neck stump before resection.



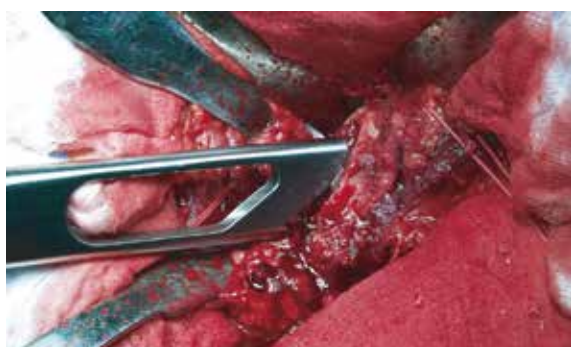Osteotomy angle assessment according to stem collar.



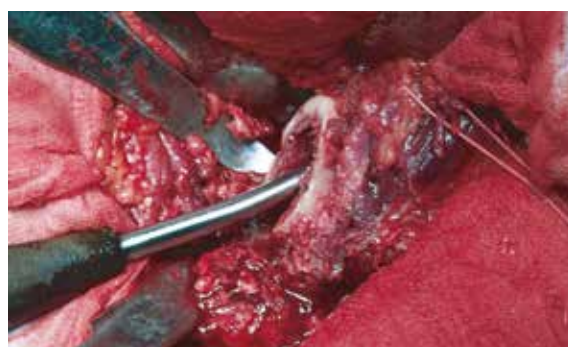Osteotomy angle in the neck area.



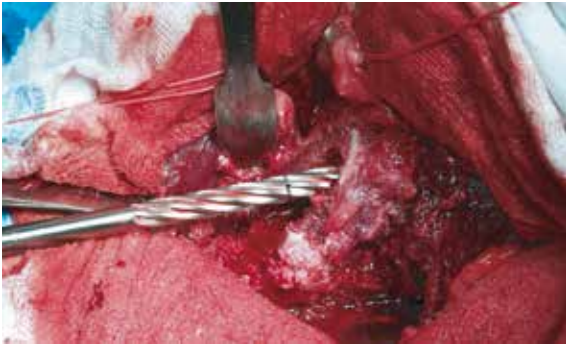Femoral neck after osteotomy.



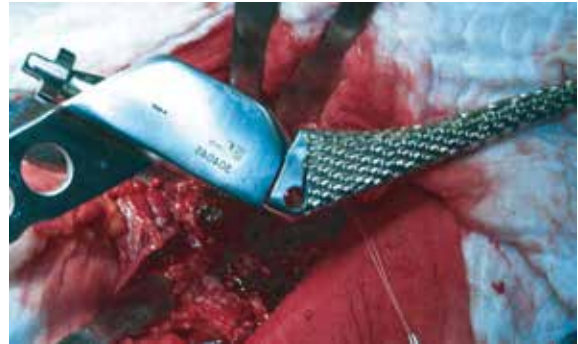Opening bone marrow canal with a special chisel.



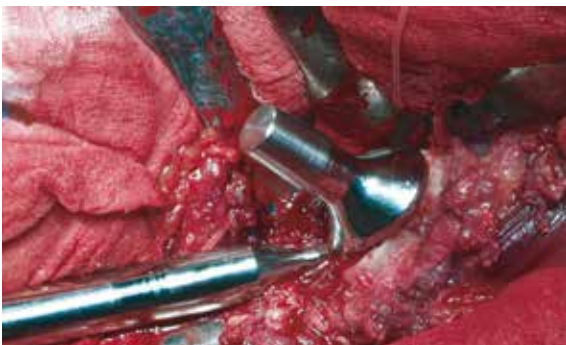Clearing bone marrow canal with a long spoon.



Cutting femoral canal.



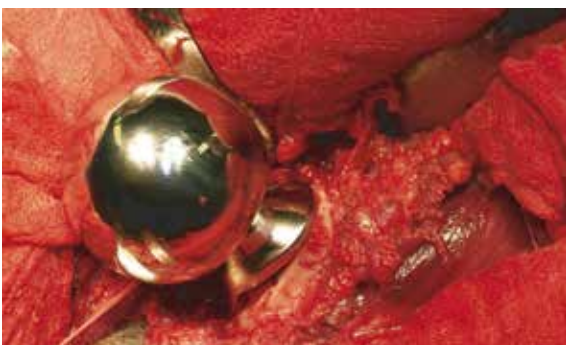Gradual rasping of the canal using cutters size 0 to 2.



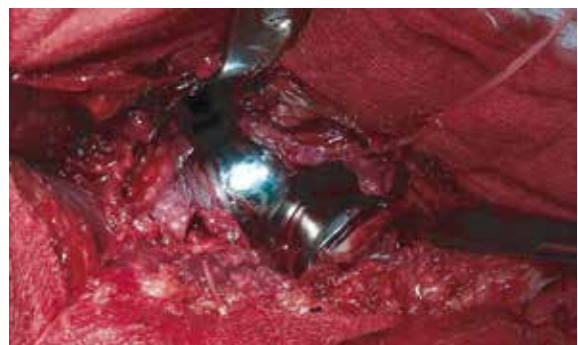Trial stem insertion.



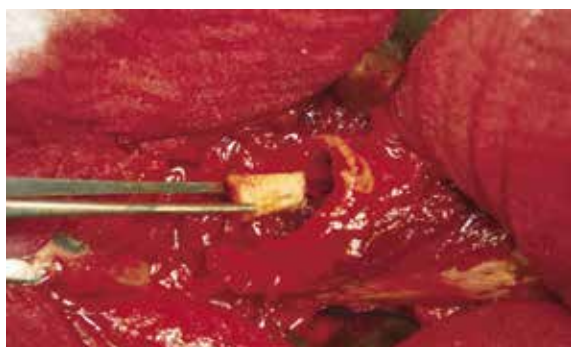Measuring head size, correct value is 46mm (center).



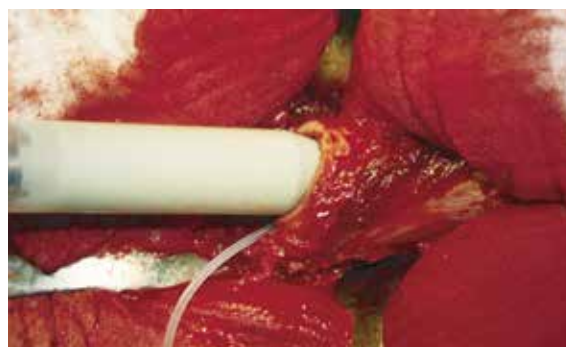Modular head applied to the head.



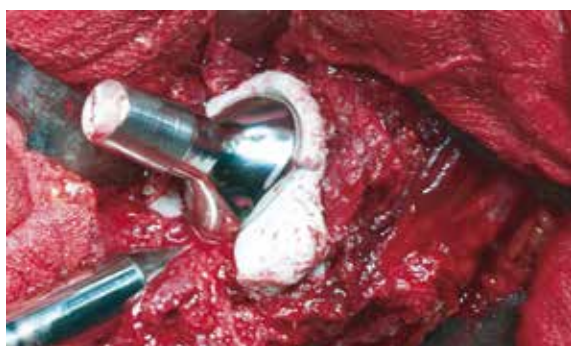Trial implant fitting.



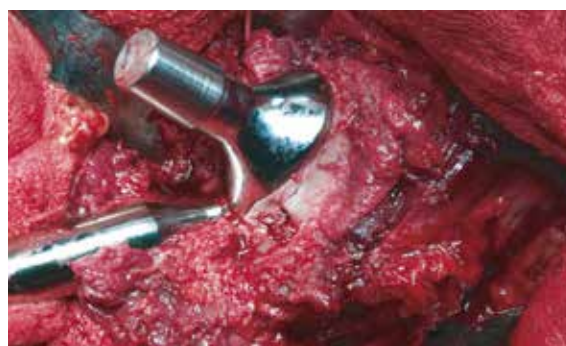Insertion of plug into bone marrow canal.



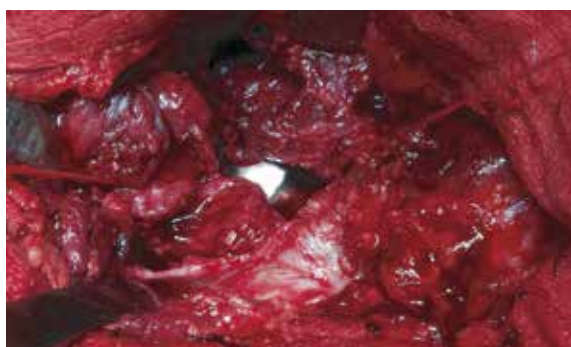
Application of cement into femoral canal.



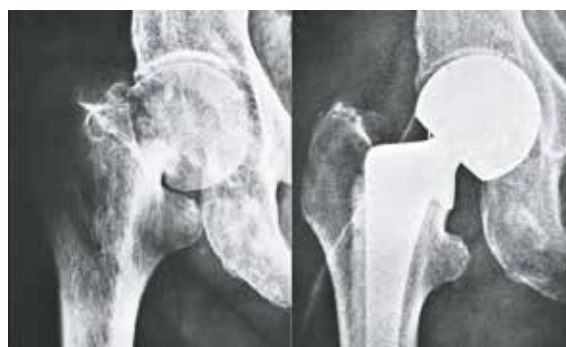Stem insertion.



Removing excess cement.



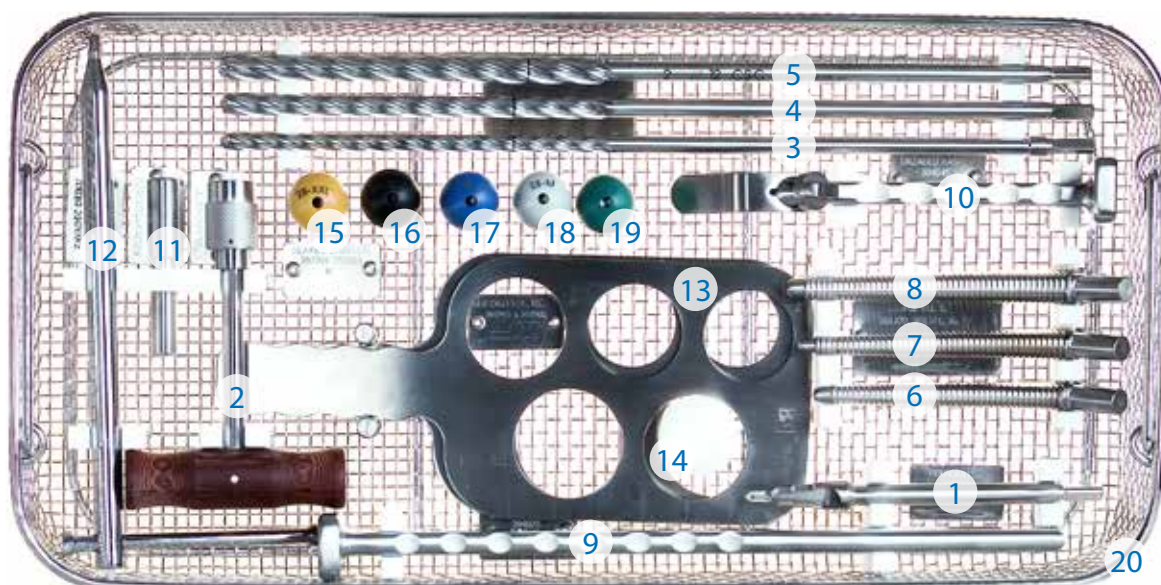
Status after definitive fitting before capsule suture.



Pre-surgery and post-surgery x-ray.

Instrumentation Set

The set of instruments is placed in a one cassette to facilitate overview of the instruments and to keep them in place during transportation, storage, preparation, sterilization, and surgery. The instruments are arranged as shown in the following illustration. When in transit, the cassette is placed into a styrofoam casing and put into a cardboard box.



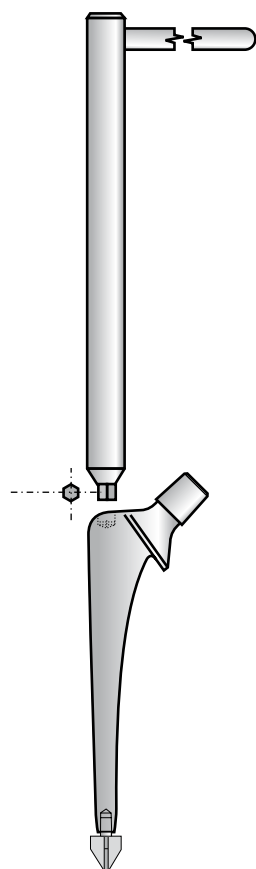
INSTRUMENTS FOR APPLICATION OF HEMIARTHROPLASTY, TYPE CSB
CASSETTE LAYOUT

	Name	Qty	Order No.
1	Perforator for TEP stem	1pc	304000
2	Triangular T-head	1pc	304002
3	Cylindrical cutter ø 8mm (CSC) – triangular end	1pc	301388
4	Cylindrical cutter ø 10mm (CSC) – triangular end	1pc	301390
5	Cylindrical cutter ø 12mm (CSC) – triangular end	1pc	301392
6	Rasp for TEP stem, straight, cem. - type CSC -size 0	1pc	301370
7	Rasp for TEP stem, straight, cem. - type CSC -size 1	1pc	301371
8	Rasp for TEP stem, straight, cem. - type CSC -size 2	1pc	301372
9	Gauge chisel for TEP stem	1pc	304025
10	Rasp handle for TEP stem type SF	1pc	304045
11	Knock-out pin	1pc	304052
12	Stem guide wire SCB	1pc	301760
13	Head gauge size I	1pc	301901
14	Head gauge size II	1pc	301902
15	Trial head 28 (PA), conical 12/14 flat XXL	1pc	307201
16	Trial head 28 (PA), conical 12/14 flat XL	1pc	307202
17	Trial head 28 (PA), conical 12/14 flat L	1pc	307203
18	Trial head 28 (PA), conical 12/14 flat M	1pc	307204
19	Trial head 28 (PA), conical 12/14 flat S	1pc	307205
20	Cassette – instruments for application of cemented hemiarthroplasty type CSB	1pc	301090

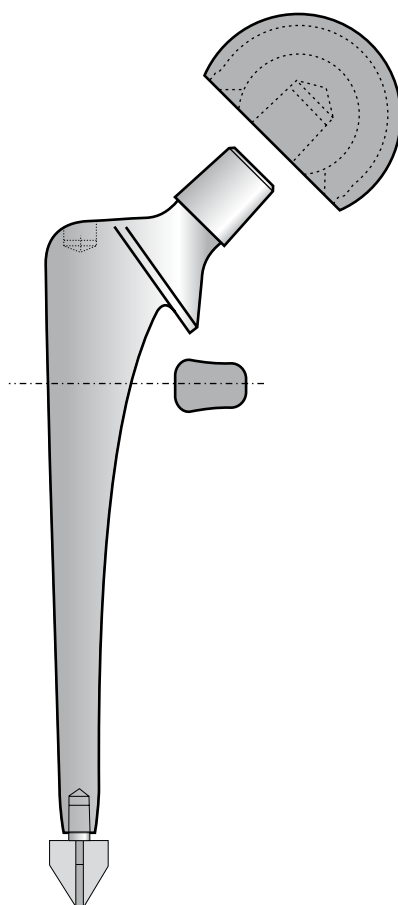


■ Hemiarthroplasty Modular Stem

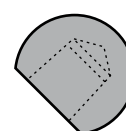
Instruments for
inserting and adjusting
stem antetorsion



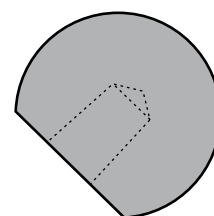
Biarticular
Head



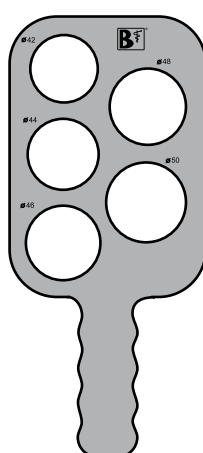
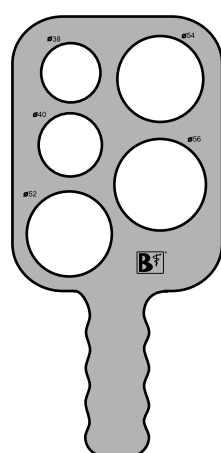
Head



Hemiarthroplasty
Head



Matrices for measuring the size of extracted head.




■

Implants


The design of cemented stem for hip hemiarthroplasty, type CSB, with a centralizer, is based on latest findings and experience with cemented prostheses; state-of-the-art technology was used in its production. Utilization of instruments supplied by the manufacturer ensures simple implantation and perfect fixation of the implant.

Cemented hemiarthroplasty stem, type CSB, designated for implantation with the aid of a PMMA centralizer and bone cement, is made of rustproof, nitrogen alloyed steel ISO 5832-9. It is delivered in 9 head diameters - 40, 42, 44, 46, 48, 50, 52, 54, and 56 mm. The stem is polished to mirror-like effect. The CCD angle is 135 degrees.

Modular stem - type CSB with centralizer



Hemiarthroplasty hip prosthesis - type CSB with centralizer




Head Diameter	Order number
38*	315900
40	315902
42	315904
44	315906
46	315908
48	315910
50	315912
52	315914
54	315916
56	315918
58*	315920
60*	315922


*available as custom-made option only



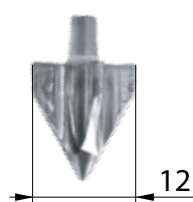
Hemiarthroplasty Head	
Head Diameter	Order number
38	324600
40	324602
42	324604
44	324606
46	324608
48	324610
50	324612
52	324614
54	324616
56	324618



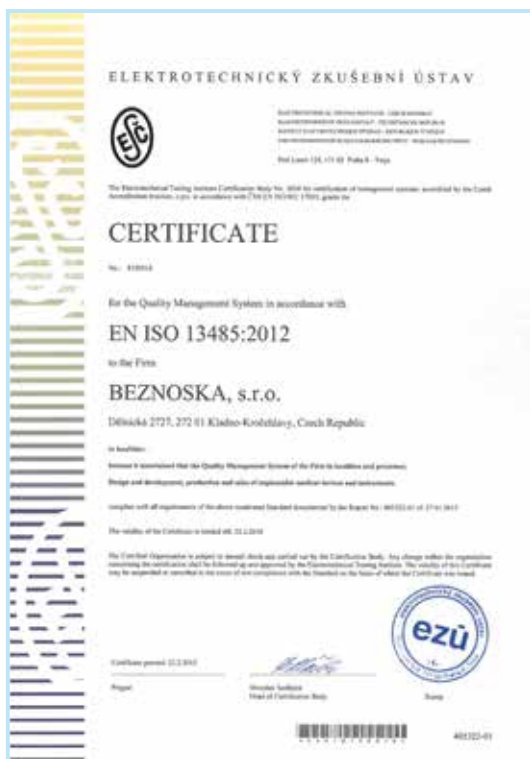Biarticular Head	
Head Diameter	Order number
42	324915
44	324920
46	324925
48	324930
50	324935
52	324940
54	324945
56	324950



Centralizér
Order number
317012



Note: All sizes to be read in mm.



Contact

Export:

tel.: +420 312 811 221
 +420 312 811 225

export@beznoska.cz